

## THE “WIDOW MAKER” WARNING SIGN OR WELLENS’ SYNDROME: A CASE REPORT

MIRJANA KARADŽIĆ<sup>1</sup>, JELENA VUČKOVIĆ-FILIPOVIĆ<sup>2</sup>, G. DAVIDOVIĆ<sup>2</sup>,  
VIOLETA IRIĆ-ČUPIĆ<sup>4</sup>, M. TASIĆ<sup>3</sup> and Z. KOVAČEVIĆ<sup>5</sup><sup>1</sup> Health Center “Dr Milan-Bane Đorđević”, Velika Plana, Serbia<sup>2</sup> Cardiology Clinic, University of Kragujevac, 34000 Kragujevac, Serbia<sup>3</sup> Interventional Cardiology, Clinical Centre Kragujevac, University of Kragujevac, 34000 Kragujevac, Serbia<sup>4</sup> School of Medicine, University of Kragujevac, 34000 Kragujevac, Serbia<sup>5</sup> Emergency Center, Clinical Center Kragujevac, University of Kragujevac, 34000 Kragujevac, Serbia

**Abstract** - Wellens’ syndrome, also known as LAD (left anterior descending) coronary T-wave syndrome, “widow maker” or warning sign, is a potentially unrecognized critical proximal LAD stenosis with possible fatal consequences. It can be associated with extensive acute anterior wall myocardial infarction, with left ventricular dysfunction and a lethal outcome within a few days after the onset of symptoms. It usually consists of a typical ECG finding in the precordial leads that represents a significant proximal LAD stenosis in patients with unstable angina pectoris. Although this syndrome is not indicated for PCI (the patient is usually pain-free at the time of electrocardiography registration), it is necessary to recognize the characteristic pattern and perform an emergency coronary angiography and percutaneous or surgical revascularisation of the affected blood vessel. Here we present the case report of a 47 year-old woman without previous anamnesis of coronary disease. On admission to the Coronary Care Unit she was chest pain-free and had all the indicators of Wellens’ syndrome.

**Key words:** T-wave, left anterior descending coronary artery (LAD), unstable angina pectoris, stenosis, ECG

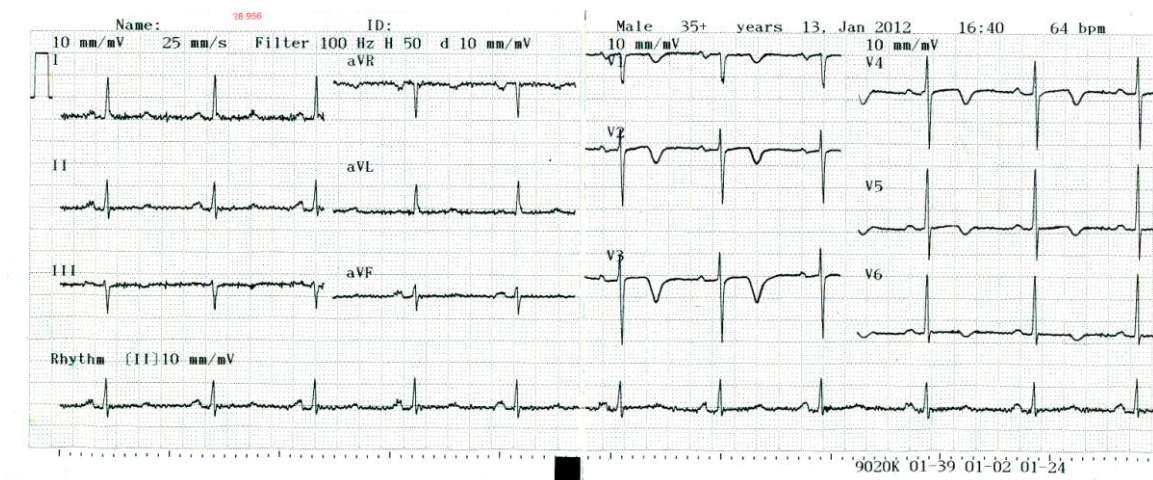
## INTRODUCTION

Wellens’ syndrome, “SQ” syndrome, LAD coronary T-wave syndrome, or “widow maker” are synonymous for the characteristic ECG pattern observed in patients with unstable angina pectoris in a chest pain-free period. It is a sign of critical proximal LAD stenosis. The changes in T-wave which are in the precordial leads are subtle and can easily be overlooked. Coronary angiography findings confirm critical LAD stenosis (Hovland et al., 2006; Nisbet et al., 2008) most frequently in the proximal part. Recognition of Wellens’ syndrome is imperative considering that 75% (Ayman et al., 2001; Stambuk et al., 2010) of patients develop an extensive acute anterior wall myo-

cardial infarction within a few days after the onset of symptoms. This case report is particularly interesting because it relates to a patient with no prior history of heart disease and with chest pain.

*Case report*

Female patient Č. M., 47 years old, was admitted to the Coronary Care Unit, Internal Clinic, Clinical Center Kragujevac due to repeated episodes of chest pain (Goor et al., 2003, Narasimhan et al., 2004) over the past two days. The pain was sharp, stabbing, intensity 8/10, localized behind the sternum, with propagation in the left shoulder, lasting 10-15 min. Associated symptoms included weakness, ma-



**Fig. 1.** Typical ECG pattern for Wellens' syndrome deep inverted symmetric T-waves in leads V2, V3, V4, biphasic T in V6, R waves are preserved

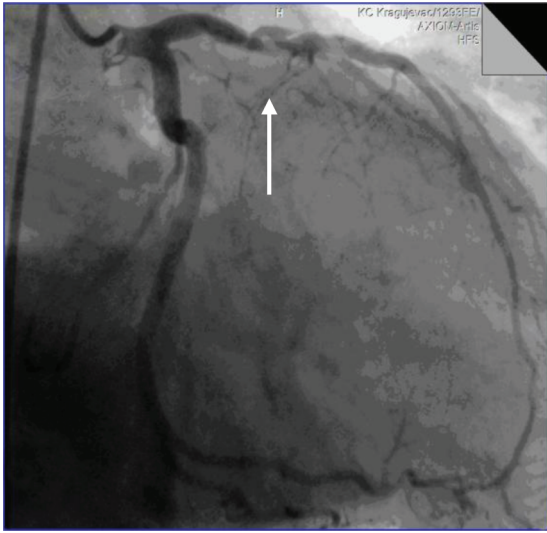
laise and profuse sweating. The first episode of chest pain was caused by exertion and stopped spontaneously. The patient denied any previous episode of chest pain (Stambuk et al., 2010; Mead et al., 2009). She had a 20-years smoker history of 20 cigarettes a day (Mead et al., 2003). In the Center for Emergency Medicine the patient received Aspirin tabl 300 mg per os and sublingual nitroglycerol and was sent to the Coronary Care Unit. At the time of admission she was pain-free.

On physical examination, heart auscultation, rhythmic action, frequency 64/min, cardiac sounds clear with no murmurs and thrills, BP=170/95 mm Hg, normal respiratory sound, respiratory frequency 18/min, SAT 98%,  $t = 37^{\circ}\text{C}$ , were registered. Other findings were in the physiological range.

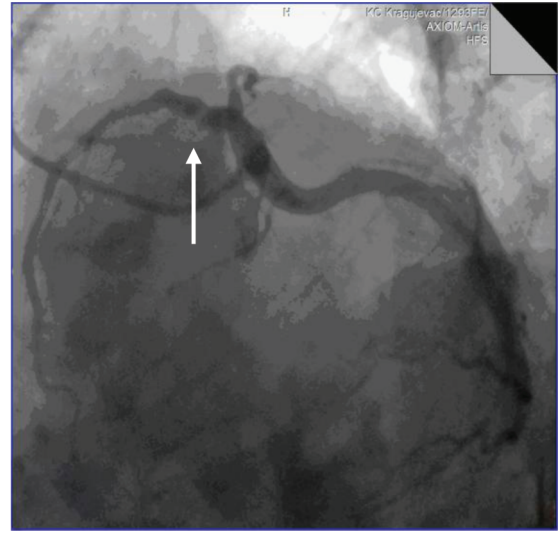
Electrocardiography (ECG) showed a normal sinus rhythm, frequency 64/min, normal axis, isoelectric ST segment, deep inverted symmetric T-waves in V2, V3, V4, up to 5 mm in V3, in V5 shallow inverted T-wave -1 mm, biphasic in V6 (Fig. 1). The pattern is typical of Wellens' syndrome (Mead et al., 2009; Nisbet et al., 2008) as a specific form of unstable angina. The patient received therapy as recommended: Clopidogrel tabl 300 mg per os and an antihyperten-

sive from a group of ACE inhibitors, Ramipril tabl 5 mg.

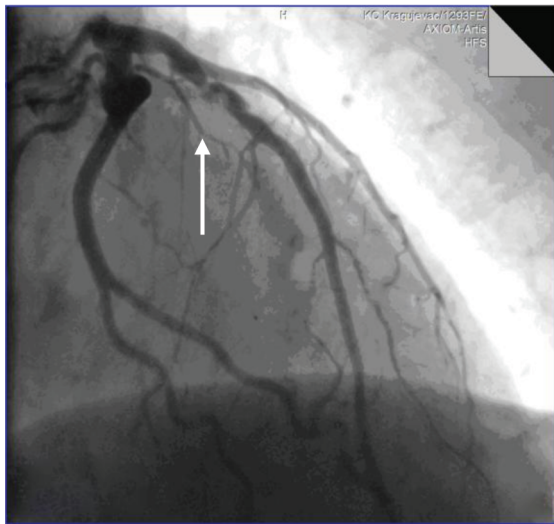
Emergency laboratory tests (Mead et al., 2009; Nisbet et al., 2008) showed that the blood glucose was an elevated 7.5 mmol/l and the presence of positive parameters of biohumoral inflammatory syndrome – CRP 76.2 IU/mg/L. Markers of myocyte necrosis (Stambuk et al., 2010; Ayman et al., 2001) were CPK 444 IU/L, CK-MB 21 IU/L, troponin 0.39  $\mu\text{g/L}$ , LDH 394 IU/L, AST 58 IU/L, which represent the baseline elevated pattern of myocyte necrosis syndrome. Repeated analyses were within reference values. Due to the assumption of Wellens' LAD coronary syndrome, a echocardiographic examination was carried out. It demonstrated normal cardiac cavity dimensions, the EF (ejection fraction) was 55%, mitral cuspises partially fibrous modified, MR (mitral regurgitation) 1+, TR (tricuspidal regurgitation) 1+. Hypokinesia (Sobnosky et al., 2006) of the apical and medial segments of the septum and the anterior wall of the left ventricle were observed, confirming ischemic changes of the myocardium. Considering the baseline elevated values of cardiac enzymes, the ECG pattern typical for Wellens' syndrome (deeply inverted symmetric T-waves in precordial leads V2, V3, V4)



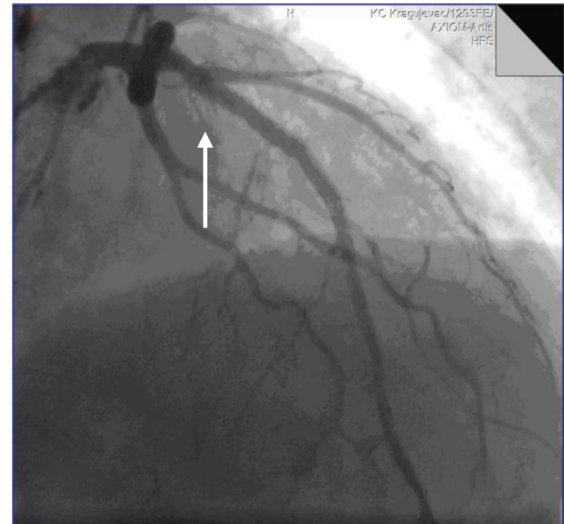
**Fig. 2.** Coronary angiography before stent implantation shows critical proximal LAD narrowing, 95%.



**Fig. 3.** Coronary angiography before stent implantation shows critical proximal LAD narrowing, 95%.



**Fig. 4.** Coronary angiography before PCI shows severe proximal LAD stenosis.



**Fig. 5.** Findings after PCI LAD stent implantation.

and echocardiographic findings that pointed to ischemia of the anterior myocardial wall and septum, the patient was referred for urgent coronary angiography (Appel-da-Silva et al., 2010; Goor et al., 2003) (Figs. 2, 3).

Coronary angiography (Ayman et al., 2001; Hovland et al., 2006) showed diffuse atherosclerotic

changes on LAD and severe stenosis caused by ex-ulcerated plaque in the proximal segment which narrows the lumen by about 95%. Other findings were in order (Figs. 2, 3). PCI (percutaneous coronary intervention) LAD ad hoc was performed after a balloon dilatation stent (Hovland et al., 2006; Grochenig, 2008) was implanted (Figs. 4, 5). During the procedure, the patient received another Clopi-



dogrel tabl 300 mg and heparin 9000 ij iv. Recommendations for further treatment: Clopidogrel tabl 75 mg 1x1 for the next six months, Aspirin tabl 100 mg 1x1, Atorvastatin tabl 40 mg 1x1. The patient was discharged from the hospital three days after the procedure.

## DISCUSSION

This case report illustrates the typical electrocardiographic features of Wellens' syndrome (Boden et al., 1989; Nisbet et al. 2008) in a 47 year-old woman with no previous history of coronary disease. The eponym is in honor of Dr J. Hein J. Wellens' who was the first, with de Zwaan and colleagues, to describe this electrocardiographic phenomenon in 1982 in a subgroup of patients with UA (unstable angina). In this group, the ECG pattern gave inverted T-waves in the precordial leads; in a high percentage it correlated with an extensive acute anterior myocardial infarction and a poor prognosis. It turned out that 75% of the patients (Narasimhan et al., 2004, Kardesoglu et al., 2003) had an extensive anterior wall myocardial infarction in spite of conservative therapy within a few days after the onset of symptoms. There are two variants of ST-T abnormalities in the precordial leads (Appel-da-Silva et al., 2010; Tatli et al., 2009) in patients with Wellens' syndrome. The larger group, type 1, encompasses 76% of patients who have deep symmetrical inverted T-waves in V2 and V3, often in V4, V5, and sometimes in V6 (Nisbet et al., 2008; Stambuk et al., 2010). The second form, type 2, have biphasic T-waves in leads V2 and V3 and this usually exists in about 24% of patients and is accompanied by a greater level of lethality (Tandy et al., 1999). These T-waves have a characteristic upsloping then sharply downsloping pattern leading to a T-wave inversion that seems to be different from the T-wave inversion of other etiologies.

Wellens' syndrome criteria are (Appel-da-Silva et al., 2010; de Zwaan et al., 1989; Tandy et al., 1999):

- History of a recent chest-pain episode;
- Chest pain with normal ECG;

- Normal or baseline elevated pattern of cardiac enzymes;
- No pathological Q waves in the precordial leads or loss of P waves;
- Biphasic T-waves in V2, V3 or deeply symmetrical inverted T-waves in V2-V5 or V6 in a pain-free period;
- Minimal (<1 mm) flat or concave ST segment elevation or isoelectric ST in V2, V3;
- Tight proximal LAD stenosis.

Wellens' criteria are quite specific for LAD coronary artery disease. All the patients in his 1988 study showed a narrowing of the proximal LAD (left anterior descending) coronary artery by 50% and more, and in 59% there was a subtotal stenosis (means 85% narrowing) or total stenosis (Tandy et al., 1999).

This pattern of ECG changes in Wellens' syndrome has been described in this case report in a female patient in a chest pain-free period. It is important to note these changes at a time when they are the only evidence of myocardial ischemia. For this reason it is necessary to do serial electrocardiograms or ECG monitoring in patients with unstable angina in a chest pain-free period. During episodes of chest pain there can be a transient pseudonormalization; T-waves become positive or more, often there, is ST segment depression or elevation (Grochenig, 2008; Tandy et al., 1999).

There are cases of Wellens' syndrome where type 1 and type 2 alternated during observation and coronary angiography demonstrated a critical medial LAD stenosis (Kardesoglu et al., 2003; Sobnosky et al., 2010).

The prognostic significance of the electrocardiographic changes characteristic of Wellens' syndrome has been demonstrated in this study where it was shown that the specificity and sensitivity of T-wave inversions in precordial leads of 2 mm and more indicated a significant LAD obstruction (69% and 89%) and the predictive value was 86% (Tandy et al., 1999).



It is obvious that it is necessary to recognize unusual Wellens' warning signs and to react promptly with aggressive treatment (Boden et al., 1989; Mead et al., 2009). An ergometer stress test is contraindicated in these patients because it can lead to infarction of the anterior myocardial wall (Goor et al., 2003), unless it is absolutely necessary for some reason and is performed with special precautions (Sobnosky et al., 2006). Diagnosis is based on the anamnesis, the baseline elevated pattern for markers of myocardial necrosis or normal values, and the most important characteristic ECG pattern. Primary conservative therapy may result in a transient improvement. Recommendations for treatment include an early invasive approach, i.e. emergency cardiac catheterization and angioplasty or surgical revascularisation CABG (coronary artery bypass graft) (Ayman and Elmenyar, 2001; Stambuk et al., 2010).

### CONCLUSION

Wellens' syndrome is a potentially unrecognized ECG manifestation of critical proximal LAD stenosis (Mead et al., 2009, Tatli et al., 2009) in patients with unstable angina pectoris in a chest pain-free period. This syndrome is a preinfarction condition of coronary artery disease with a high predictive value for the development of acute myocardial infarction. Diagnosis is based on ST segment changes in anterior precordial leads, i.e. deep symmetric inverted or biphasic T-waves, with or without minimal ST elevation (<1mm), history of a recent episode of chest pain and a normal or baseline elevated pattern of cardiac necrosis markers. Ergometry is contraindicated due to a high risk of myocardial infarction. The consequence of failure to recognize these subtle electrocardiographic patterns is an extensive acute anterior wall myocardial infarction within a few days after the onset of symptoms (Stambuk et al., 2010; Tandy et al., 1999). This can be followed by left ventricular dysfunction, malignant rhythm disorders and an often lethal outcome. The necessity of recognizing the characteristic ECG pattern in precordial leads in the ST segment and T-waves at a time when they are the only sign of

myocardial ischemia is obvious. As this indicates the potentially lethal subocclusion of LAD, it is an imperative to react promptly and aggressively with a coronary angiography to confirm the diagnosis of Wellens' syndrome, followed by percutaneous or surgical revascularisation (CABG). We have shown the importance of Wellens' syndrome in our case report because our patient had no prior history of chest pain, the electrocardiographic findings could be seen as unimportant, but a coronary angiography showed severe proximal LAD stenosis. The patient was immediately stented and a lethal outcome was prevented.

### REFERENCES

- Hovland, A., Bjornstad, H., Stant, U. and H. Vik-Mo (2006), Reversible ischemia in Wellens' syndrome. *Journal of Nuclear Cardiology*, Volume 13, Number 6, e13 – e15.
- Elmenyar, A.A. (2001): Wellens' syndrome, *Heart Views* vol. 1, 408 - 410
- Boden, W.E., Bough, E.W., Benham, J., and R.S. Shulman (1983). Unstable angina with episodic ST segment elevation and minimal creatine kinase release culminating in extensive recurrent infarction. *J Am Coll Cardiol*; 2, 11-20
- de Zwann, C., Bar, F.W., Janssen, J.H., Cheriex, E.C., Dassen, W.R. and P. Brugada (1989) Angiographic and clinical characteristics of patients with unstable angina showing an ECG pattern indicating critical narrowing of the proximal LAD coronary artery. *Am Heart J.*, 117, 657-65.
- Kardesoglu, E., Celik, T., Cebeci, B.S., Cingozbay, B.Y., Dincturk, M. and E. Demiralp (2003) Wellens' Syndrome: A case report. *The Journal of International Medical Research*; 31, 585-590
- Tatli, E. and M. Aktoz (2009): Wellens' syndrome: The electrocardiographic finding that is seen as unimportant. *Cardiology Journal*. Vol 16. No. 1. pp. 73-75q
- Grochenig, H.P. (2008): Wellens' sign, *Wien Klin Wochenshr*; 120/11 – 12:335
- Campos Appel-da-Silva, M., Zago, G., Pereira Abelin, A., Pin, W.O., Pereira Dutra, O. and O. Vaz (2010) : Wellens' syndrome, *Cardiol.* vol. 94 no.4 São Paulo.
- Narasimhan, S. and G.M. Robinson (2004): Wellens' syndrome: A combined variant. *I Postgrad Med*; 50, 73 – 74
- Mead, N.E. and K. P. O' Keefe (2009): Wellens' syndrome: An ominous EKG pattern. *Journal of Emergencies, Trauma and Shock*; 2(3), 206–208.

- Nisbet, B.C. and G. Zlupko (2008): Wellens' syndrome: case report of critical proximal left anterior descending artery restenosis. *J Emerg Med.* 2010 Sep; **39**(3), 305-8.
- Sobnosky, S., Kohli, R. and S. Bleibel (2006): Wellens' syndrome. *The Internet Journal of Cardiology.* Volume 3 Number 1.
- Stambuk, K., Pavlović, N., Manola, S., Krcmar, T., Pintarić, H. and D. Delić-Brkljacić (2010): Wellens' syndrome in a female patient presenting to emergency room after resolving exercise-induced chest pain. *Acta Clin Croat*; **49**, 73-76
- Tandy, T.K., Bottomy, D.P. and J.G. Lewis (1999): Wellens' syndrome. *Emerg Med*; **33**, 347-351
- Goor, Y., Magal, R., Goor, O., Frimerman, A. and S. Cabili (2003): Critical Myocardial Ischemia: Minor Electrocardiographic Changes: Wellens' syndrome. *IMAJ*; **5**, February: 129 - 130