

Vitamin B complex treatment improves motor nerve regeneration and recovery of muscle function in a rodent model of peripheral nerve injury

Predrag Nedeljković^{1,*}, Dragana Zmijanac^{2,3}, Biljana Drašković-Pavlović³, Milijana Vasiljevska³, Dragana Vučević³, Biljana Božić^{2,3,#} and Marko Bumbaširević^{4,5}

¹ *Institute for orthopedic-surgical diseases, "Banjica", Belgrade, Serbia*

² *University of Belgrade, Faculty of Biology, Belgrade, Serbia*

³ *Institute for Medical Research, Military Medical Academy, Belgrade, Serbia*

⁴ *University of Belgrade, Faculty of Medicine, Belgrade, Serbia*

⁵ *Orthopedic Clinic, Clinical Center of Serbia, Belgrade, Serbia*

Corresponding authors: *nedeljkovicpredrag@gmail.com; #biljana@bio.bg.ac.rs

Received: March 20, 2016; **Revised:** April 21, 2016; **Accepted:** May 4, 2016; **Published online:** October 31, 2016

Abstract: It is well known that the peripheral nervous system has a good potential for regeneration. The aim of this study was to explore the effects of vitamin B therapy (with a complex of vitamins B1, B2, B3, B5, B6, and B12) on motor nerve recovery after femoral nerve injury. Our study was conducted on an experimental animal model of femoral nerve injury in rats. All animals used in the experiment were subjected to the same set of analyses. A behavior test was used for the assessment of motor function recovery. Body weight was measured and electromyography was performed in order to assess recovery of quadriceps muscle. Samples of muscles and nerves were used for counting nuclei and determining nuclear density. The results of this study showed enhanced functional recovery, including improved walking, a decreased level of muscle atrophy and better electromyography recovery after administration of vitamin B complex. Further, after 14 days of treatment with the vitamin B complex nuclear nerve and muscle density was significantly lowered. In conclusion, using a model of femoral nerve injury we demonstrated that the application of vitamin B complex improved recovery of motor nerve in rats.

Key words: vitamin B complex; peripheral nerve injury; functional recovery; nuclear density

INTRODUCTION

The incidence of peripheral nerve injury (PNI) in developed countries is around 20 (13-23)/100000 per year [1]. The consequences of PNI include partial or complete loss of motor, sensory and autonomous function of the severed part of the body. The gold standard for the treatment of PNI is primary surgical reconstruction (neurorrhaphy). After the wound heals, patients are usually referred for physical therapy (which includes different types of exercises, electrotherapy, ultrasound therapy, etc.) to achieve the best possible reinnervation. The clinical outcome of motor function recovery (MFR) in adults is often disappointing (unlike sensory, which usually achieves a good degree of recovery) [2]. It is estimated that only 50% of patients with PNI achieve good functional motor recovery, and that only 10% achieve complete (or al-

most complete) recovery of motor function [3,4]. Well known factors that limit MFR are age, proximity of injury (the more proximal, the worse the prognosis), type of injury (sharp, blunt, avulsion, conqasation), complexity of injury, timing and method of treatment. As a consequence of any severe injury of peripheral nerves, the predictable proximal and distal (Wallerian) axonal degeneration occurs. The processes of axonal degeneration and myelin sheath disintegration start within 24-48 h in rats [5,6] and within several days in humans [7,8]. Schwann cells assume a dual role of degradation of myelin and axonal debris, and they proliferate within the basal lamina of the remaining endoneurial connective tissue sheath. As they proliferate they become densely packed in longitudinal rows (bands of Büngner) and become ready to accept regrowing axon buds and remyelinate the advancing

regenerating axons [9]. Therapeutic treatments that improve axonal regeneration could improve functional recovery. It was shown that administration of different vitamins of B complex had a prophylactically and therapeutically positive effect on peripheral nerve regeneration. These effects are manifested in reducing Schwann cell atrophy and disintegration of the myelin sheath and reducing axonal degeneration [10,11]. Nerve conduction velocity and axonal outgrowth also showed increased rates when rats were treated with vitamin B complex (B1, B6, B12) [12]. Our study was undertaken to investigate the relation between the effect of vitamin B complex (B1, B2, B3, B5, B6, B12) on motor nerve regeneration and muscle function.

MATERIALS AND METHODS

Experimental animals

A total of 48 adult male Albino Oxford (AO) rats, weighing between 250 and 300 g, were used in the experiments. The animals were randomly divided into three groups (4 per group). The first group comprised “operated animals” (O), in which transection of the motor branch of the femoral nerve was performed with immediate reconstruction using a technique of termino-terminal anastomosis. The second group (OT) included animals that were surgically treated in the same way but additionally receiving vitamin B complex therapy. The third group included “sham operated” animals (S), which underwent the same procedure (dissection of the motor branch of the femoral nerve), but without transection of the nerve. All groups were examined 1, 3, 7 and 14 days after injury.

All animals used in the experiment were subjected to the same set of analyses. Before killing, a behavior test was used to assess motor function recovery (walking test). Body weight was measured and electromyography (EMG) was performed in order to assess recovery of the quadriceps muscle. Subsequently, motor branches of the femoral nerve (both reconstructed and intact contralateral) and quadriceps muscles (muscle innervated by an “operated”, reconstructed nerve, and muscle innervated by an intact contralateral nerve) were isolated. Muscle mass was also measured. Isolated nerves and muscles were further used for histo-

logical analysis. The rats were killed by intravenous injection of ketamine/xylazine in a lethal dose. All procedures were done in accordance with the Guide for the Care and Use of Laboratory Animals.

Experimental model of injury of rat femoral nerve motor branch transection

All animal experiments were approved by the Ethics Review Committee for Animal Experimentation of Military Medical Academy and Ministry of Agriculture and Environmental Protection Republic of Serbia, Veterinary Directorate No. 323-07-7363/2014-05/5.

Controlled transection of the peripheral nerve is a well-described model for the examination of peripheral nerve regeneration. Animals aged between 2.5 and 3 months were anesthetized by intraperitoneal application of ketamine (50 mg/kg; Ketalar, Eczacıbasi, Turkey) and xylazine (5 mg/kg; Rompun, Bayer, Turkey). Following anesthesia, the animals were positioned and identification of the motor branch of the femoral nerve of the left back leg of the rat was done through skin incision in the left groin and femoral region under aseptic conditions. The motor branch was identified just before entry in the quadriceps muscle. Using microscope magnification, transection of the branch was done and immediate reconstruction performed using a 10-0 non-absorbable suture in the form of termino-terminal anastomosis. The skin was sutured using 4-0 absorbable suture (Peters Surgical, Paris, France).

Vitamin B complex administration

Treatment with vitamin B complex (Beviplex®, Galenika a.d. Belgrade, Serbia) was investigated. Each ampoule of Beviplex (2ml) contains B1 (40mg), B2 (4mg), B3 (100mg), B5 (10mg), B6 (8mg) and B12 (4µg). The dose was 1.85 ml/kg/day. Vitamin B complex was injected intraperitoneally immediately after the operation and every morning from the day of the operation until the day of sacrifice.

Behavioral test

To assess motor function recovery, a behavioral test (walking test) was used [13]. Injury of the mo-

tor branch of the femoral nerve causes a deficit of knee extension and lack of support of body mass during walking, which is necessary for the uplift of the contralateral leg. To assess this deficit, animals were filmed from behind while walking. The deficit is manifested as an internal rotation of the foot of the injured leg during bearing (opposite to external rotation of the uninjured leg). The angle is formed by the vertical line that passes through the foot longitudinally and the horizontal line of the bearing surface (inner angle). This angle represents the parameter used to assess walking abnormality. The angle is measured when toes detach from the walking surface and the foot is parallel to the transverse plane surface. Values of the angle were measured using Adobe Photoshop CS6 program (Adobe Systems Inc, San Jose, CA, USA).

Assessment of muscle atrophy

After the animal were killed, muscles were isolated from injured and non-injured legs and their mass was measured. The muscle atrophy was calculated as the percentage of body atrophy ($[\text{mass of contralateral muscle} - \text{mass of injured muscle}] / \text{body mass} \times 100$).

Electrophysiological assessment of recovery

Electromyography (EMG) is a diagnostic method for the assessment of motor function of the muscle, and, indirectly, of the motor nerve that innervates the muscle. The EMG device used was an Animal & Human Physiology Transducer kit (iWorx/CBScience Inc, Washington Center, USA). EMG measurements were performed on the 1st, 3rd, 7th and 14th days after injury/reconstruction. Animals were anesthetized and positioned as described above. An electrode for electrical grounding was applied to the right back leg. Both injured and contralateral nerve and muscle were dissected using the same technique and magnification. The motor branch of the femoral nerve was stimulated distal to the site of injury/reconstruction using a stimulatory electrode; muscle activity (action potentials) was measured by a monopolar electrode applied to the muscle itself. The EMG percentage was calculated as the percentage of EMG activity in the contralateral muscle ($\text{EMG of injured muscle} / \text{EMG of contralateral muscle} \times 100$).

Determining nerve nuclear density of quadriceps muscle and femoral nerve

Samples of muscles and nerves for histological evaluation were prepared and stained using hematoxylin and eosin (H&E) (Laboratory for Pathohistology and Cytology HistoLab, Belgrade). Samples of muscles and nerves were examined under the microscope (Leica, Solms, Germany) and photographed under 40x magnification. ImageJ was used to count nuclei and determine nuclear density ($\text{nuclei}/\text{mm}^2$) (National Institutes of Health, Bethesda, Maryland, USA).

Statistical analysis

Group mean values were compared using a two-sided Student's t-test for independent samples. The accepted level of significance was 5%. Values are shown as mean values with standard deviation (SD).

RESULTS

Single-frame motion analysis

Both groups with severed nerves had a significant increase in the foot-base angle immediately after injury and steady improvement over time (Fig. 1 A and B). The highest values of foot-base angle were found on the first day post injury (110.7 ± 3.1 and 109.8 ± 3.4 degrees for operated, untreated (O) and operated animals treated with vitamin B complex (OT), respectively). There was a highly statistically significant difference for both groups compared to the non-operated (S) animals (74.0 ± 5.6), with no significant difference between O and OT animals. Both groups showed a decrease in the values of the angle over time (3rd and 7th days post injury) with significant differences between O (104.2 ± 3.6 for the 3rd and 94.3 ± 5.5 for the 7th day) and OT (99.0 ± 3.2 , 3rd day, 90.9 ± 2.8 , 7th day) compared to S (75.3 ± 7.6 , 3rd day, 68.7 ± 5.0 , 7th day) group. However, differences between the O and OT groups were still insignificant. Fourteen days after injury, a statistically significant difference between values of the foot-base angle of the O and OT groups (91.9 ± 3.6 and 79.1 ± 2.2 degrees, respectively) was noticed.

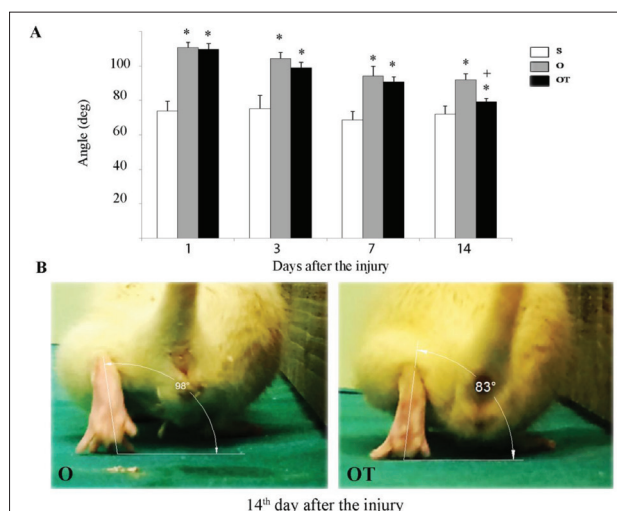


Fig. 1. Functional recovery after femoral nerve injury and end-to-end repair assessed by single frame motion analysis (foot-base angle). **A** – Diagram of the angle formed by a vertical line that passes through the foot longitudinally, and a horizontal line of the bearing surface (inner angle). Results are shown as the mean±SD. * $p < 0.05$ vs. S; † $p < 0.05$ vs. O. **B** – internal rotation of the foot of the injured leg in O and OT rats. S – sham animals; O – operated animals; OT – operated animals treated with vitamin B complex.

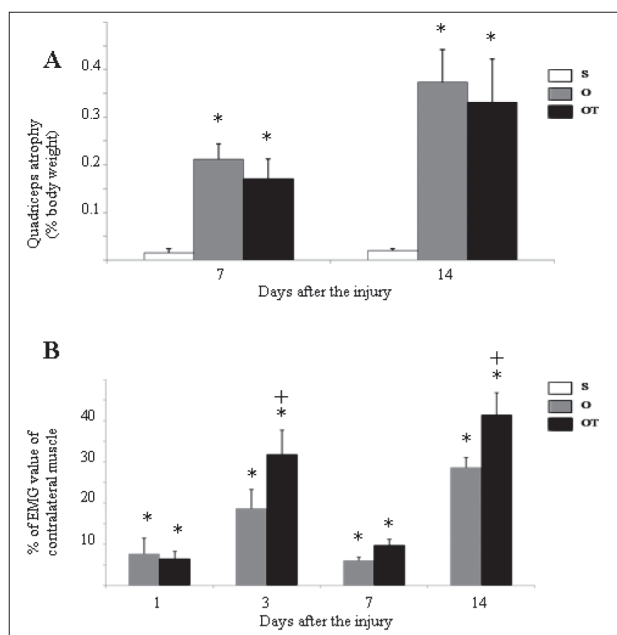


Fig. 2. Functional recovery after femoral nerve injury and end-to-end repair assessed by atrophy of quadriceps muscle (**A**) and quadriceps electromyography activity (**B**). Results are shown as the mean±SD. * $p < 0.05$ vs. S; † $p < 0.05$ vs. O. S – sham animals; O – operated animals; OT – operated animals treated with vitamin B complex.

Quadriceps muscle mass

Fig. 2 A shows muscle atrophy after femoral nerve transection and reconstruction. There was no muscle atrophy in either O or OT group on the 1st and 3rd day after injury (data not shown). Seven days after injury, the quadriceps muscle in both operated groups (O and OT) showed a significant degree of muscle atrophy (0.21 ± 0.03 and 0.17 ± 0.04 , respectively) compared to the S group. However, there was no significant difference in muscle mass between the two operated groups (O and OT). Fourteen days after injury, a progression of muscle atrophy was seen (0.37 ± 0.07 and 0.33 ± 0.09 for O and OT group, respectively) in comparison to the O and OT groups at postoperative day 7. Still, there was no significant difference between the O and OT groups.

Quadriceps EMG activity

Compared to the contralateral muscle, quadriceps EMG activity decreased significantly immediately after injury in both operated groups (7.67 ± 3.84 for O and 6.52 ± 1.83 for the OT group on day 1 after injury) with no significant difference between the operated groups (Fig. 2 B). These values increased on day 3 with a statistically significant difference between the operated groups (18.66 ± 4.70 for O, 31.84 ± 5.89 for OT). There was decrease in EMG values on the 7th day post injury (6.07 ± 0.80 for O, 9.79 ± 1.48 for OT), followed by a significant increase on day 14 (28.60 ± 2.49 for O, 41.37 ± 5.47 for OT). Treatment with vitamin B complex induced a statistically significant increase in EMG activity at all investigated time points post injury, except on day 1.

Nerve nuclear density

Fig. 3 shows the nuclear densities of operated femoral nerves after injury. Both operated groups (O and OT) displayed a significant increase in nerve nuclear density when compared to the S group (2512.2 ± 334.3 for the 1st, 5607.8 ± 778.1 for the 3rd, 4062.6 ± 580.8 for the 7th and 3887.7 ± 764.9 for the 14th day for group O, and 2149.8 ± 229.1 for the 1st, 3862.4 ± 464.5 for the 3rd, 4034.0 ± 269.1 for the 7th and 3052.2 ± 276.5 for the 14th day, for OT group). The S group showed significantly lower values (1471.5 ± 255.3 for the 1st, 1846.7 ± 347.6

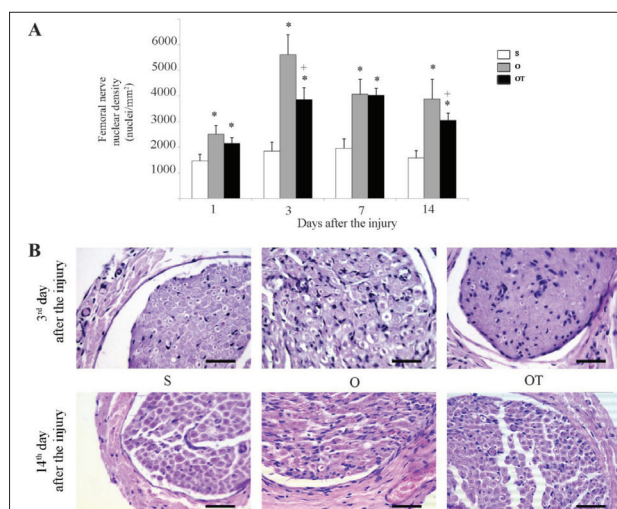


Fig. 3: Temporal changes in nerve nuclear density after femoral nerve injury. **A** – Diagram of the nuclear density in regenerating nerves at different time points post-injury. Results are shown as the mean±SD. * $p < 0.05$ vs. S; * $p < 0.05$ vs. O. **B** – light micrographs of transverse sections of H&E stained femoral nerve 14 days after the injury. Scale bar 50 μ m. S – sham animals; O – operated animals; OT – operated animals treated with vitamin B complex.

for the 3rd, 1966.3±351.3 for the 7th and 1581.4±277.5 for the 14th day). The increase in nuclear density in the OT group was less than in the O group, particularly on the 3rd and 14th postoperative days (Fig. 3A). At Figure 3B micrographs of H&E stained femoral nerve transverse sections 3 and 14 days after the injury are presented.

Muscle nuclear density

Nuclear densities of operated quadriceps muscles during investigated period were shown in Fig. 4. There was no significant increase in muscle nuclear density between O, OT, and S groups (722.1±74.8, 742.0±121.6 and 764.9±67.7, respectively) on the 1st day following the injury. Significant increase of muscle nuclear density between operated animals (groups O and OT) and S group was found on day three (1214.6±128.6 and 1215.7±115.7 for O and OT groups, and 865.3±73.4 for the S group), but there was no difference between O and OT group. Compared to post-operative day 3, an insignificant decrease in nuclear density was found in both operated groups on day 7 (1135.4±97.1 in group O and 1109.9±153.8 in OT group). On the 14th day, muscle nuclear density considerable increased in the O group (1594.4±265.2)

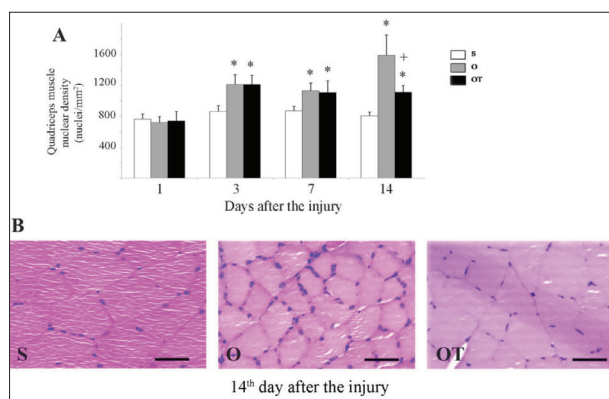


Fig. 4: Time-course of changes in muscle nuclear density after femoral nerve injury. **A** – Diagram illustrating the quadriceps muscle nuclear density at different time points post-injury. Results are shown as the mean±SD. * $p < 0.05$ vs. S; * $p < 0.05$ vs. O. **B** – light micrographs of transverse sections of H&E-stained quadriceps muscle 14 days after the injury. Scale bar 50 μ m. S – sham animals, O – operated animals, OT – operated animals treated with vitamin B complex.

compared to the OT (1114.5±86.1) and S (810.0±47.3) groups, which retained a similar nuclear density as on the 7th day (Fig. 4A). Micrographs of quadriceps muscle transverse sections 14 days after injury, stained with H&E, are shown in Fig. 4B.

DISCUSSION

This study demonstrated that intraperitoneal administration of vitamin B complex during the immediate post-injury period resulted in better recovery of quadriceps muscle function after transection of the motor branch of the femoral nerve and end-to-end anastomosis in rats. Using single-frame analysis (walking test), measurement of muscle atrophy, EMG activity, and nerve and muscle nuclear density we have shown that treatment with vitamin B complex improved functional recovery of the peripheral nerve after injury. Both operated groups (O and OT) showed a significant increase in foot-base angle compared to the S group. This is the result of the impaired function of the quadriceps muscle, which is the sole extensor of the knee joint. Similar to humans, this leads to an inability to bear body weight during the single-support phases required for the swing of the contralateral leg during walking. Increased body-weight load in the stance phase causes abnormal bending in the knee joint, lifting of the heel and internal rotation of the paw [14].

A steady decrease in the foot-base angle was noticed during the first 14 days following injury, which is in correlation with the incipient recovery of quadriceps function. The foot-base angle decreased more in the group of animals treated with vitamin B complex than in untreated group, and this difference was statistically significant at the 14th day after the injury. These results imply that muscle function recovers faster with vitamin B complex therapy as a result of improved recovery of the motor nerve after transection and reconstruction. The obtained data are in correlation with other literature results that showed improved muscle function recovery under vitamin B12 therapy after ulnar to musculocutaneous nerve transfer [15].

The first significant changes in muscle mass, as regards both operated groups, were seen seven days after injury with progressive atrophy until the 14th day. However, there was no statistically significant difference between the operated groups, although the loss in muscle mass was lower in animals treated with vitamin B complex. This finding can be explained by the fact that denervated muscle needs time to express changes that will lead to atrophy of its muscle fibers, and eventually lead to a reduction in muscle mass. As it is known, atrophy is caused by a decreased level of transcription and translation in affected muscle. Decreased levels of synthesis and increased levels of degradation of myofibrillar proteins lead to decreased muscle mass [16,17]. Recovery of muscle mass can approach pre-operative values even when the number of regenerating axons is lower than normal, because each regenerating axon can reinnervate as many as 4-5 times the normal number of muscle fibers to compensate for the reduced numbers of axons that succeed in reaching the denervated muscle [18].

Electrodiagnostic studies provide objective and quantitative means of evaluating muscle function. Direct comparison of compound muscle action potentials can be useful in assessing differences in extent of nerve regeneration [19]. It is well known that injured axons retain some degree of conductivity a few days after injury, until they undergo degeneration. Motor axons remain excitable for up to 7 days after injury [17]. Our results are in correlation with previous literature data as the lowest levels of EMG (compared to the uninjured side) were found on the 7th day after injury [17]. An increase in EMG values is

shown on the 14th postoperative day, with a significant difference between the treated and untreated groups. According to literature data, vitamin B12 therapy can improve the process of nerve regeneration through the promotion of axonal transport and regeneration [20-22]. Therefore, the increased EMG activity seen in the treated group can be partially explained by the effects of B12 and other B vitamins of the complex. In addition, this treatment facilitates the development and maturation of the neuromuscular junction [23-25] and accelerates the myelination of peripheral axons in rats [20-22]. Moreover, it was shown that the administration of vitamin B complex increases nerve conduction velocity and axonal outgrowth in acrylamide-induced neuropathy in rats [11,12].

The nuclear density of the femoral nerve distal to the injury site increased significantly in the days after the injury. This result is in correlation with previously published articles about the peripheral nerve response to injury [26]. Femoral nerve nuclear density was increased in both operated groups (O and OT) when compared to the S group at all time-points following the injury. The most pronounced difference in femoral nerve nuclear density between the O and OT groups was found on the 3rd and 14th postoperative days. Liao et al. [15] showed that most of the nuclei in reconstructed nerve 30 days after the injury represented Schwann cells, while macrophages were less abundant. On the other hand, the peak of macrophage infiltration happens from the 3rd to 7th post-injury days. It is known from literature data that antiinflammatory drug therapy has a role in improvement of nerve regeneration after peripheral nerve [15] and spinal cord injury [27]. We may presume that the noted decrease in nuclear nerve density after the application of vitamin B complex after the injury may also be a consequence of lowered levels of inflammation. Further, we may assume that vitamin B complex therapy lowered the level of Schwann cells dedifferentiation and myelin degradation. Consequently, the lower level of Schwann cell proliferation may result in lower femoral nerve nuclear density. With this in mind, future studies need to investigate which cells populations decrease after treatment with vitamin B complex.

Muscle nuclear density showed a similar trend of changes. There was a significant increase of muscle nuclear density in muscle innervated with an injured

nerve compared to muscle innervated with an uninjured nerve. The peak of this increase was obtained on day 14, when a significant difference in muscle nuclear density was detected between OT and O animals, with lower values of muscle nuclear density in the treated group, which is in correlation with obtained results for nerve cellular density. Denervated muscle shows a compensatory myogenic response in forming new muscle fibers from satellite cells on the surfaces of muscle fibers have undergone some degree of atrophy (parent cells) or within the spaces surrounded by the basal laminae of dead muscle fibers [28]. Lower levels of muscle nuclear density may suggest that a smaller number of denervated muscle fibers underwent atrophy or cell death after treatment with vitamin B complex. Thus, there is decreased compensatory myogenic response, which leads to decreased muscle nuclear density. Improvement in nerve-regenerating processes also reduces muscle nuclear density by shortening the denervation period of the muscle and thus shortening the time in which a compensatory myogenic response can occur.

In conclusion, the results of this study indicate that treatment with vitamin B complex immediately after injury and reconstruction of the peripheral motor nerve improves recovery of the injured nerve in rats. In humans, nerve repair is compromised by delayed treatment, the long distance between injury site and target organ, higher rates of inflammation, associated injuries and a higher possibility of infection. Therefore, the effect of vitamin B complex therapy after peripheral nerve injury in humans remains to be explored.

Acknowledgments: The authors are grateful to Professor Aleksandra Korać and her staff for her valuable help and consultations regarding the histological analysis. The study was financed by the Serbian Ministry of Science (Grant 175033) and the Military Medical Academy Institutional Grant MFVMA/10/16-18.

Authors' contribution: PN performed the experiments, generated the data and drafted the manuscript. DZ, DBP, DV, MV and BB participated in carrying out the experiments. DZ generated the data and prepared the figures. BB designed the study. BB and MB coordinated the research, reviewed the manuscript and supervised the study. All authors read and approved the final manuscript. BB and MB contributed equally to this work.

Conflict of interest disclosure: The authors state that there is no conflict of interest.

REFERENCES

1. Asplund M, Nilsson M, Jacobsson A, von Holst H. Incidence of traumatic peripheral nerve injuries and amputations in Sweden between 1998 and 2006. *Neuroepidemiology*. 2009;32(3):217-28.
2. Scholz T, Krichevsky A, Sumarto A, Jaffurs D, Wirth GA, Paydar K, Evans GR. Peripheral nerve injuries: an international survey of current treatments and future perspectives. *J Reconstr Microsurg*. 2009;25(6):339-44.
3. Brushart T. Preferential reinnervation of motor nerves by regenerating motor axons. *J Neurosci*. 1988;8(3):1026-31.
4. Sunderland S. *Nerve injuries and their repair: A critical appraisal*. Edinburgh, New York: Churchill Livingstone; 1991. 538 p.
5. Lubinska L. Early course of Wallerian degeneration in myelinated fibres of the rat phrenic nerve. *Brain Res*. 1977;130(1):47-63.
6. Mileidi R, Slater CR. On the degeneration of rat neuromuscular junctions after nerve section. *J Physiol*. 1970;207(2):507-28.
7. Chaudhry V, Cornblath DR. Wallerian degeneration in human nerves: serial electrophysiological studies. *Muscle Nerve*. 1992;15(6):687-93.
8. Gilliatt RW, Hjørth RJ. Nerve conduction during Wallerian degeneration in the baboon. *J Neurol Neurosurg Psychiatry*. 1972;35(3):335-41.
9. Terzis JK, Smith KL. Repair and Grafting of the Peripheral Nerve. In: McCarthy JG, editor. *Plastic Surgery*. 3rd ed. Philadelphia: W.B. Saunders Company; 1990. p. 630-98
10. Kato Y, Tanaka T, Isawa S, Matsuda A, Nakazawa T. Quantitative studies of histological findings on acrylamide-induced neuropathy. Degenerative changes and effect of vitamin B complex. *Vitamins*. 1977;51:197-206.
11. Ohnishi A, Kuroiwa Y, Ohgo T. The effect of methylcobalamin on the experimental acrylamide neuropathy – Morphometric study. *Jpn J Clin Pharm Ther*. 1979; 10:247-51.
12. Fujii A, Matsunomo H, Yamamoto H. Effect of vitamin B complex on neurotransmission and neurite outgrowth. *Gen Pharmac*. 1996;27(6):995-1000.
13. Irintchev A, Simova O, Eberhardt K, Morellini F, Schacher M. Impacts of lesion severity and tyrosine kinase receptor B deficiency on functional outcome of femoral nerve injury assessed by a novel single-frame motion analysis in mice. *Eur J Neurosci*. 2005;22(4):802-8.
14. Irintchev A. Potentials and limitations of peripheral nerve injury models in rodents with particular reference to the femoral nerve. *Ann Anat*. 2011;193(4):276-85.
15. Liao WC, Chen JR, Wang YJ, Tseng GF. Methylcobalmin, but not methylprednisolone or pleiotrophin, accelerates the recovery of rat biceps after ulnar to musculocutaneous nerve transfer. *Neuroscience*. 2010;171(3):934-49.
16. Higashino K, Matsuura T, Sukanuma K, Yukata K, Nishisho T, Yasui N. Early changes in muscle atrophy and muscle fiber type conversion after spinal cord transection and peripheral nerve transection in rats. *J Neuroeng Rehabil*. 2013;10(1):46.
17. Quan D, Bird SJ. Nerve conduction studies and electromyography in the evaluation of peripheral nerve injuries. *Univ Pennsylvania Orthop J*. 1999;12:45-51.

18. Rafuse VF, Gordon T. Self-reinnervated cat medial gastrocnemius muscles. I. Comparison of the capacity of regenerating nerves to form enlarged motor units after extensive peripheral nerve injuries. *J. Neurophysiol.* 1996;75(1):268-81.
19. Wood MD, Kemp SW, Weber C, Borschel GH, Gordon T. Outcome measures of peripheral nerve regeneration. *Ann Anat.* 2011;193(4):321-33.
20. Yamatsu K, Kaneko T, Kitahara A, Ohkawa I. Pharmacological studies on degeneration and regeneration of peripheral nerves. (1) Effects of methylcobalamin and cobamide on EMG patterns and loss of muscle weight in rats with crushed sciatic nerve. *Nippon Yakurigaku Zasshi.* 1976;72(2):259-68.
21. Watanabe T, Kaji R, Oka N, Bara W, Kimura J. Ultra-high dose methylcobalamin promotes nerve regeneration in experimental acrylamide neuropathy. *J Neurol Sci.* 1994;122(2):140-3.
22. Reyes-Garcia G, Caram-Salas NL, Medina-Santillan R, Granados-Soto V. Oral administration of B vitamins increases the antiallodynic effect of gabapentin in the rat. *Proc West Pharmacol Soc.* 2004;47:76-9.
23. Vasilescu C, Florescu A. Peripheral neuropathy with a syndrome of continuous motor unit activity. *J Neurol.* 1982;226(4):275-82.
24. Sasaki H, Matsuzaki Y, Meguro K, Ikarashi Y, Maruyama Y, Yamaguchi S, Sekizawa K. Vitamin B12 improves cognitive disturbance in rodents fed a choline-deficient diet. *Pharmacol Biochem Behav.* 1992; 43 (2):635-9.
25. Yamazaki K, Oda K, Endo C, Kikuchi T, Wakabayashi T. Methylcobalamin (methyl-B12) promotes regeneration of motor nerve terminals degenerating in anterior gracile muscle of gracile axonal dystrophy (GAD) mutant mouse. *Neurosci Lett.* 1994;170(1):195-7.
26. Shea J, Garlick J, Salama M, Mendenhall S, Moran L, Agarwal J. Side-to-side nerve bridges reduce muscle atrophy after peripheral nerve injury in a rodent model. *J Surg Res.* 2014;187(1):350-8.
27. Bao F, Chen Y, Dekaban GA, Weaver LC. Early anti-inflammatory treatment reduces lipid peroxidation and protein nitration after spinal cord injury in rats. *J Neurochem.* 2004;88(6):1335-44.
28. Borisov AB, Dedkov EI, Carlson BM. Interrelations of Myogenic Response, Progressive Atrophy of Muscle Fibers, and Cell Death in Denervated Skeletal Muscle. *Anato Rec.* 2001;264(2):203-18.